

Figure S1 TEM image of nano-MgO particles

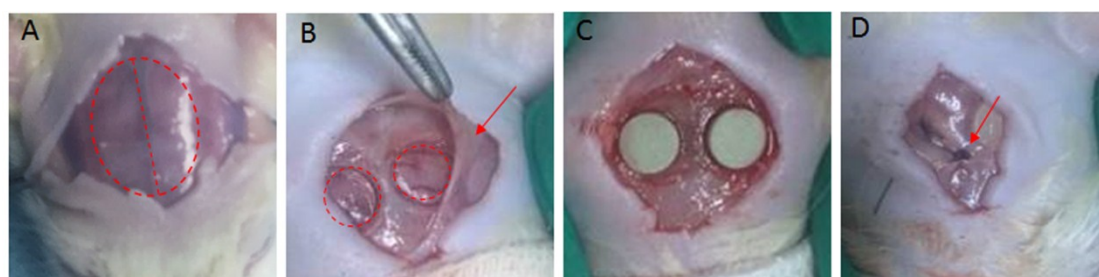


Figure S2 Operative procedure of rat critical size calvarial defect creation and caution. (A)The bone was exposed and the defect created by incision and retraction of the skin. (B)Periosteum(show as the red arrow) overling the calvarium and two 5-mm diameter calvarial defect were created by a trephine(show as the red circles) . (C)The bone cement was implanted in the defect and (D) the periosteum was sutured by a 4-Monocryl suture.

References: