

Supplementary materials

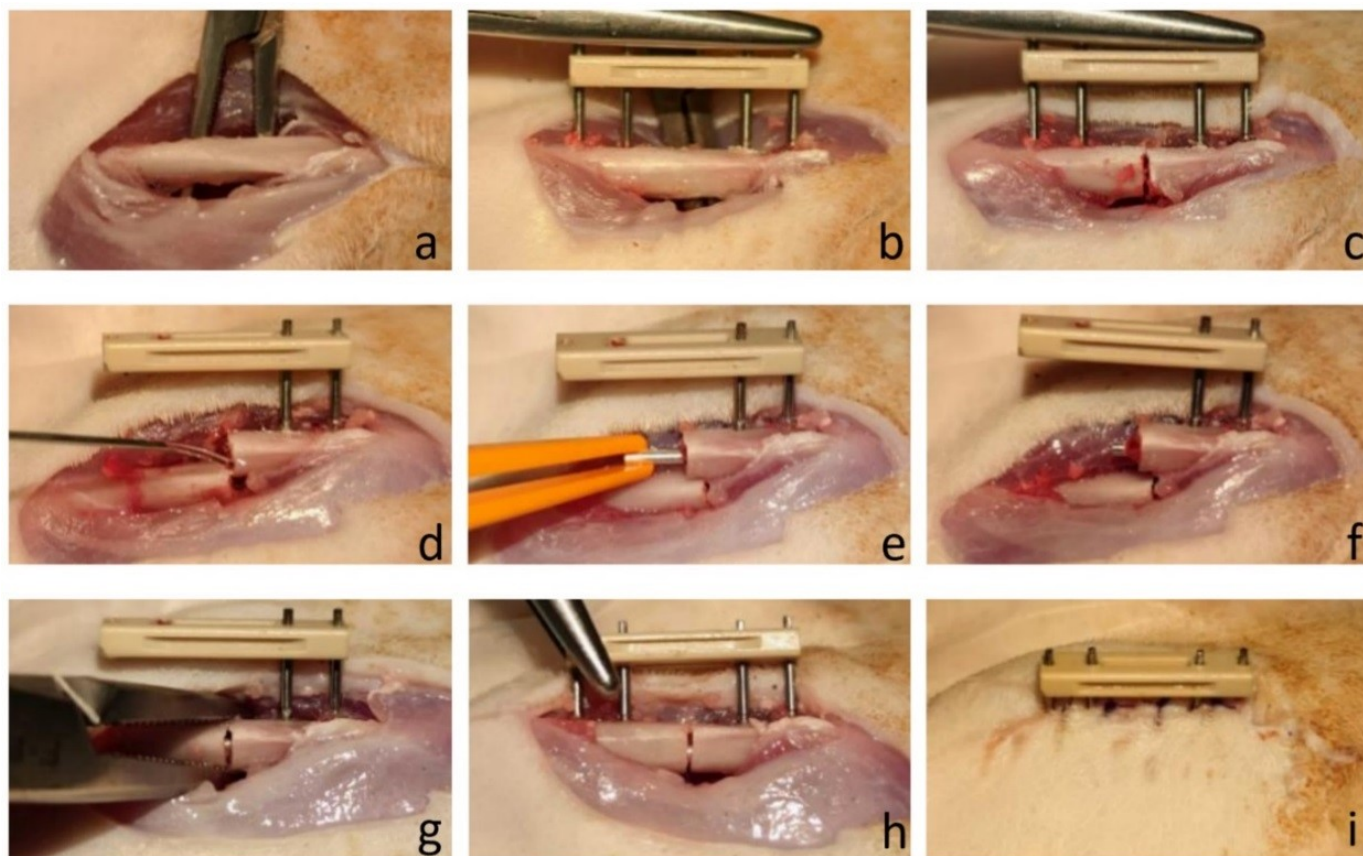


Figure. S1. Surgical procedure.

- a. Exposure of the femoral shaft via lateral approach;
- b. Mounting the external fixation device;
- c. Fracture induction by osteotomy;
- d. Wound irrigation to removal tissue and metal debris;
- e. Insertion of Mg pin with plastic forceps;
- f. Mg pin implantation in the medullary cavity;
- g. Fracture reduction of the distal femur;
- h. Final fracture stabilization with the fixator;
- i. Wound closure.

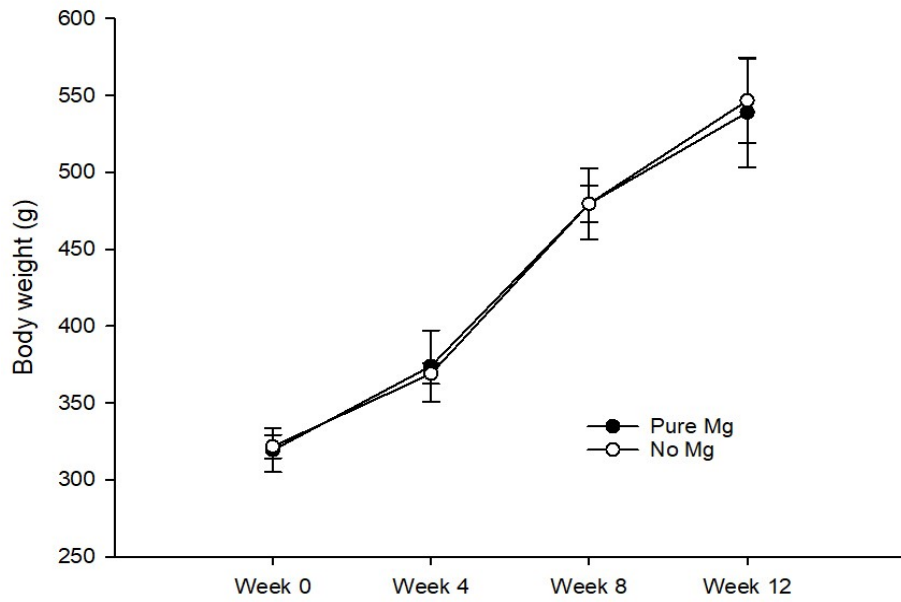


Figure. S2. Post-operative growth curve (body weight, g)

Video-clip. Animal status at day-1 after surgery.