

Supplementary Information

**Polydopamine-Coated Triamcinolone Acetonide Acetate Nanocrystals:  
Prevention of Postoperative Peritoneal Adhesion by Combining Anti-  
inflammation, Oxidative Stress Scavenging and Cytokine Adsorption**

Yaodong Liu<sup>a</sup>, Daiheng Ji<sup>a</sup>, Sixuan Liu<sup>b</sup>, Xiaoxue Qi<sup>a</sup>, Chenyi Lin<sup>a</sup>, Hui Liu<sup>b</sup>, Yajie Ji<sup>b</sup>, Yu Liu<sup>a,c\*</sup>, Weiyue Lu<sup>a</sup>.

<sup>a</sup> Department of Pharmaceutics, School of Pharmaceutical Sciences, Fudan University, Shanghai, 201203 China. E-mail: 23211030018@m.fudan.edu.cn.

<sup>b</sup> Shanghai Shuguang Hospital Affiliated with Shanghai University of Traditional Chinese Medicine, Department of Breast Surgery, 201203 China.

<sup>c</sup> State Key Laboratory of Advanced Drug Formulations for Overcoming Delivery Barriers, Shanghai, 201203 China.

Table S1. Peritoneal adhesion score

Adhesion score	
0	No adhesions
1	One thin adhesional band
2	More than one thin adhesional band
3	One thick adhesional band with a central attachment point
4	More than one thick adhesional band, or broad-based disc-shaped adhesions requiring blunt dissection
5	Multiple disc-shaped adhesions, or very thick adhesions with neovascularization requiring sharp dissection

Table S2. Granuloma neovascularization score

Score	
0 (None)	No neovascularization observed in tissue samples
1 (Mild)	Sparse distribution of small new microvessels in local areas
2 (Moderate)	Moderate density of neovascularization with partial branching structures in multiple regions
3 (Severe)	Extensive and dense neovascular network with prominent vascular plexuses and luminal dilation

Table S3. Fibrous tissue hyperplasia score

Score	
0 (None)	No fibrosis observed
1 (Mild)	Mild fibrosis (scattered spindle-shaped fibroblasts)
2 (Moderate)	Moderate fibrosis (densely packed fibroblasts with visible mitotic figures)
3 (Severe)	Severe fibrosis (marked proliferation of myofibroblasts with cellular atypia)

Table S4. Inflammation severity score

Score	
0 (None)	No inflammatory cell infiltration
1 (Mild)	Mild inflammatory cell infiltration (scattered lymphocytes or plasma cells)
2 (Moderate)	Moderate inflammatory cell infiltration (focal aggregates of lymphocytes, plasma cells, and/or neutrophils)
3 (Severe)	Severe inflammatory cell infiltration with microabscess formation and/or prominent neovascularization




Fig S1. Appearance of TAA NC and TAA@PDA prepared with different feeding ratios (TAA:DA, m/m).

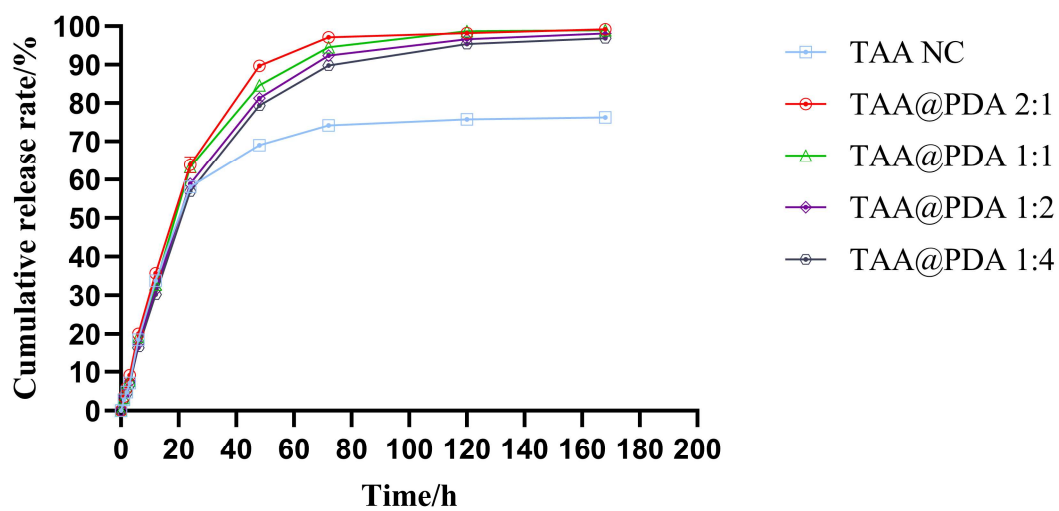


Fig S2. Effect of different feeding ratios (TAA:DA, m/m) on drug release behavior of TAA@PDA.

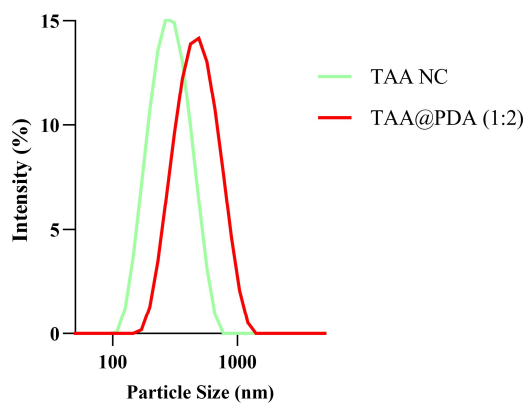


Fig S3. Size distribution of TAA NC and TAA@PDA (1:2).

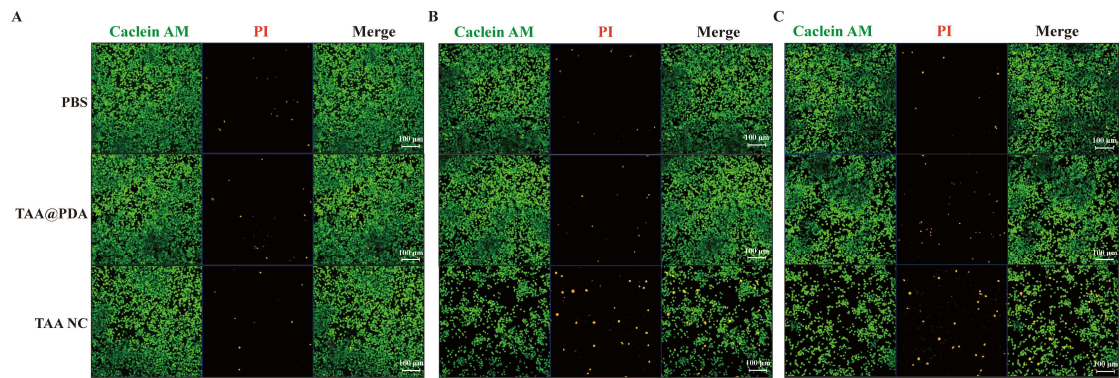


Fig S4. Live/Dead cell staining of Raw 264.7 cells following TAA@PDA treatment (A) 0.25 mg/mL; (B) 0.5 mg/mL; (C) 1 mg/mL (Green: live cells; Orange: dead cells).

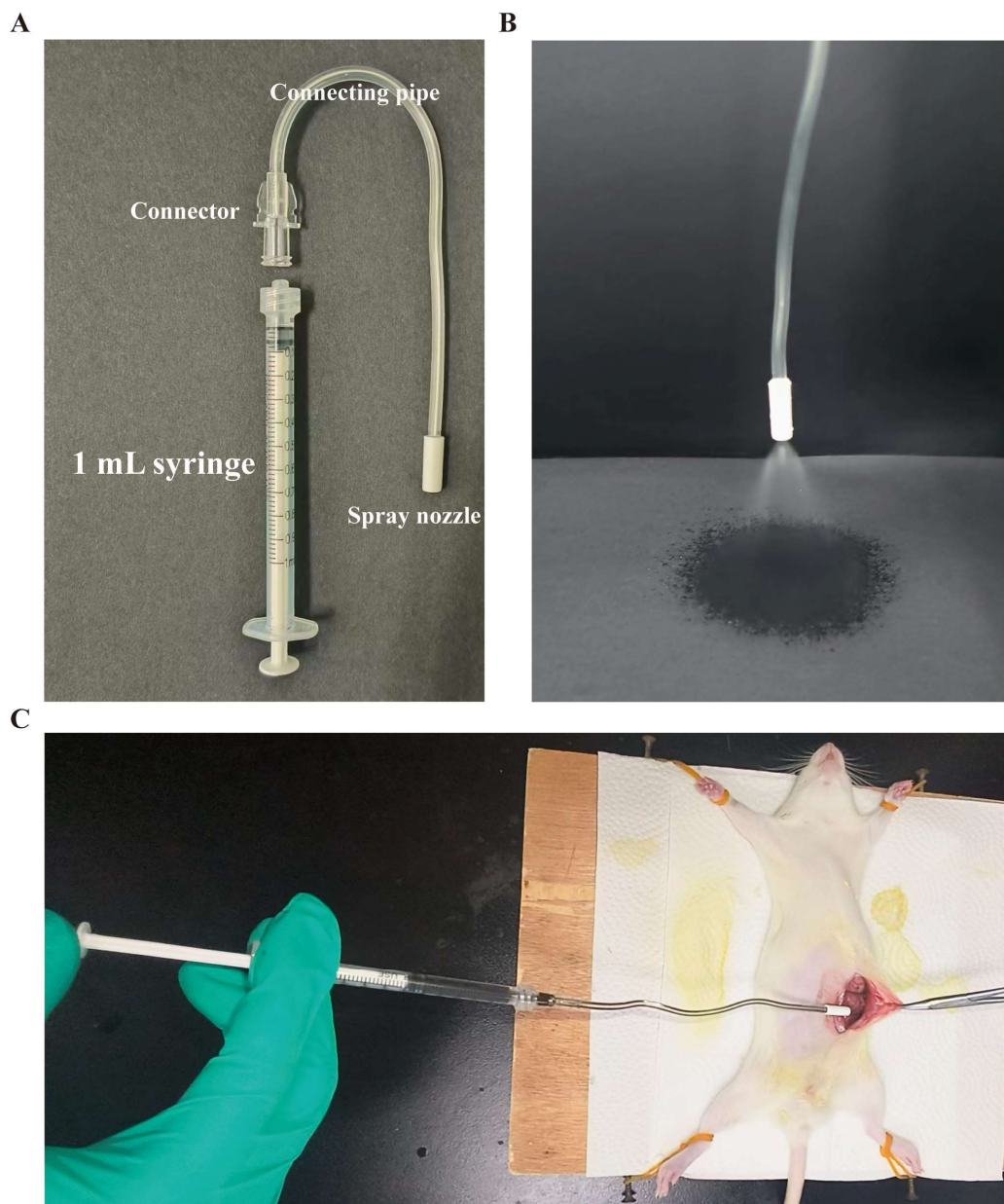


Fig S5. (A) Schematic diagram of the administration device; (B) spraying process; (C) example images of the administration procedure.

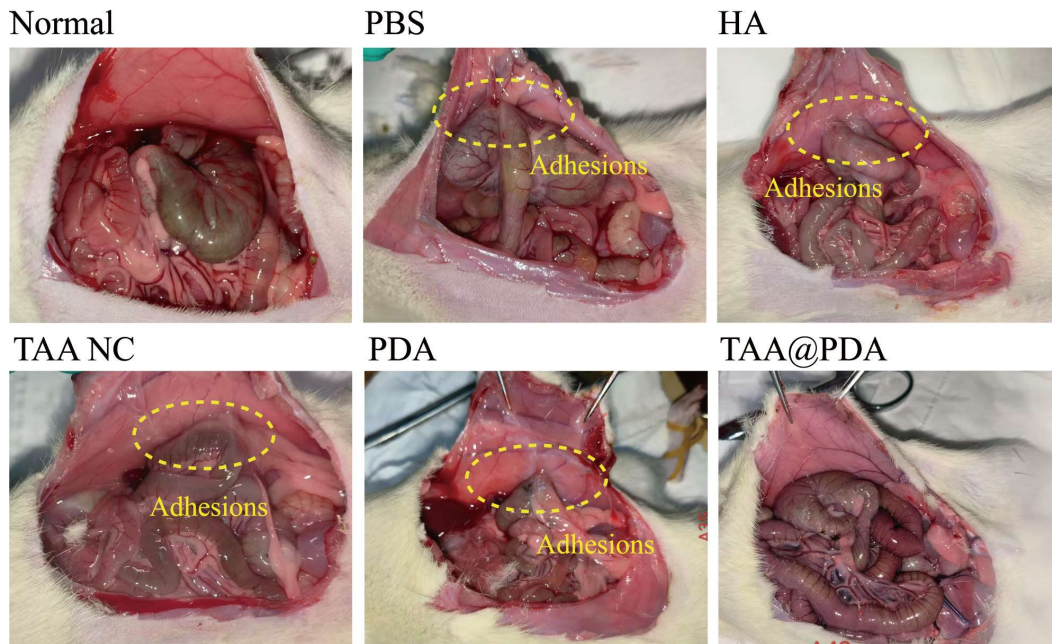


Fig S6. Photographic documentation of peritoneal adhesions in rats across experimental groups.

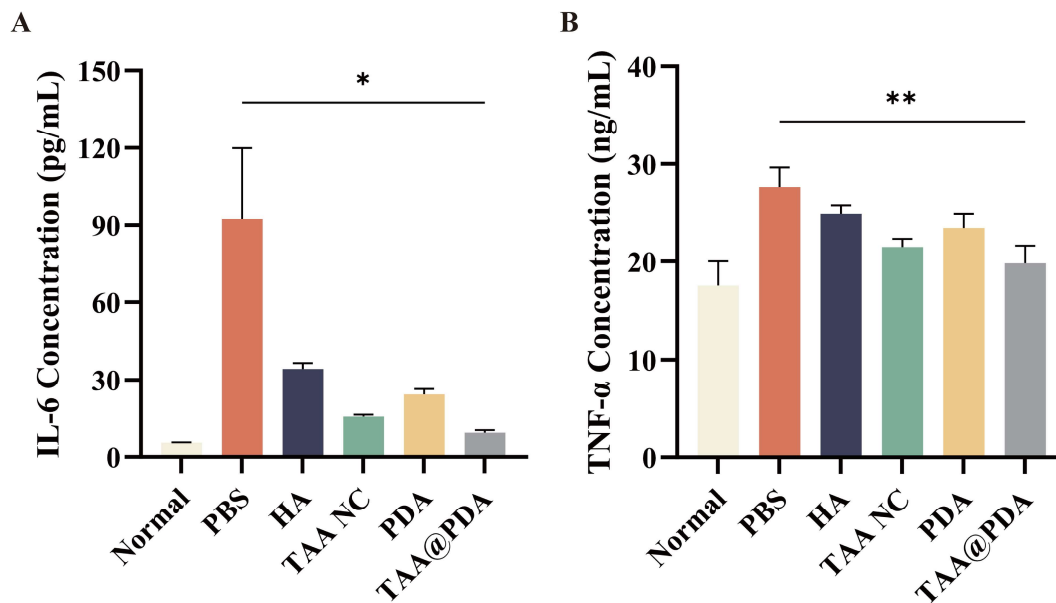


Fig S7. ELISA analysis results of serum inflammatory cytokine: (A) IL-6, (B) TNF- $\alpha$  (n=4, mean $\pm$ SD). Statistical significance: \*p<0.05, \*\*p<0.01, \*\*\*p<0.001.

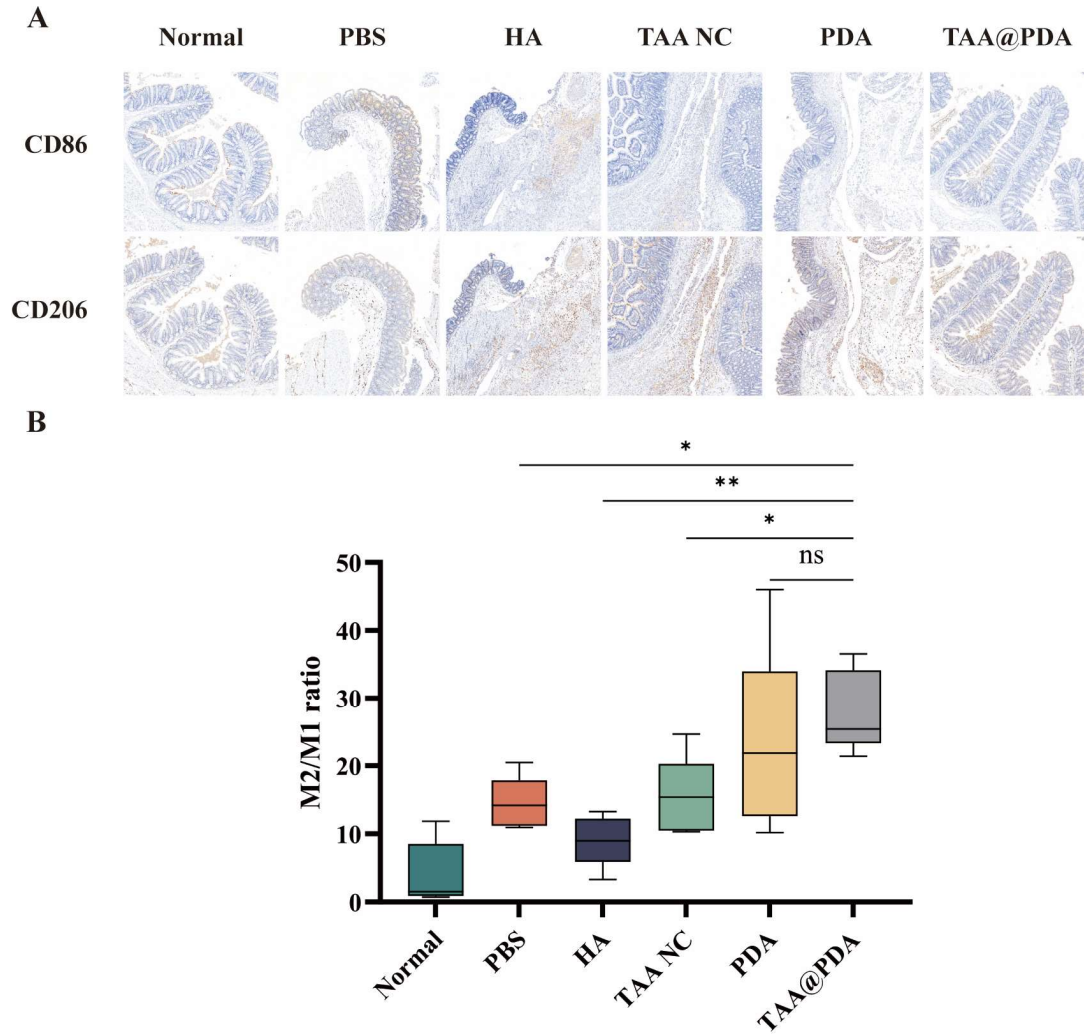


Fig S8. Immunohistochemical results of macrophage polarization (A) and analysis of M2/M1 ratio (B) (n=6, mean±SD).

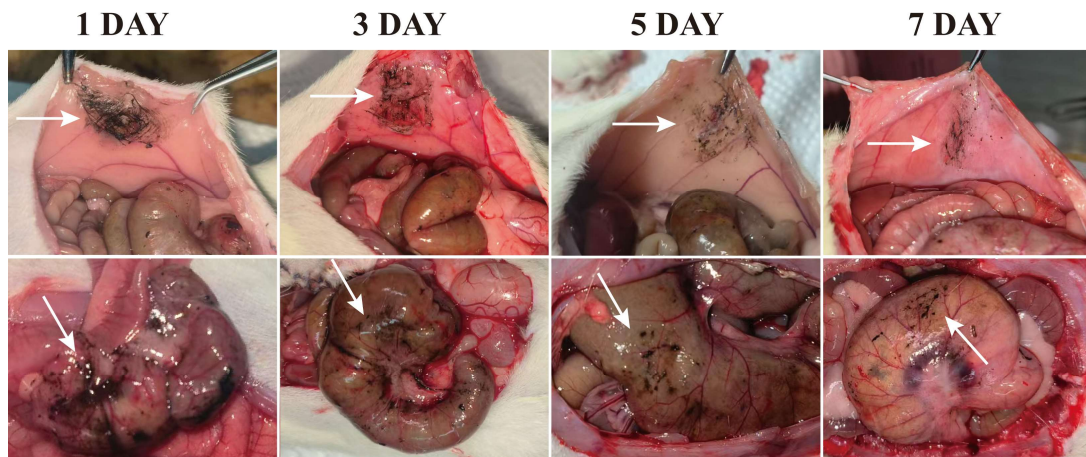


Fig S9. Retention of TAA@PDA at abdominal wall and cecal injury sites (white arrows: TAA@PDA).

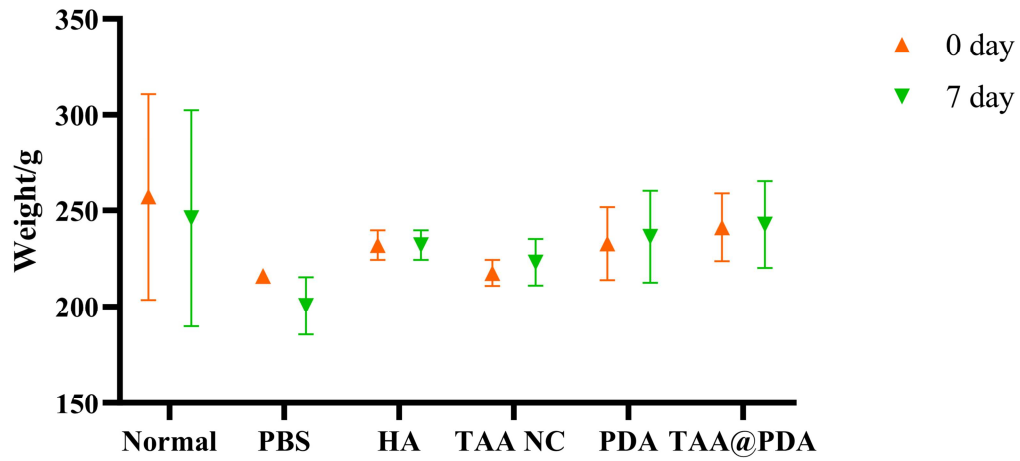


Fig S10. Changes in body weight of rats before and after 7-day treatment in each group (n=4, mean±SD).

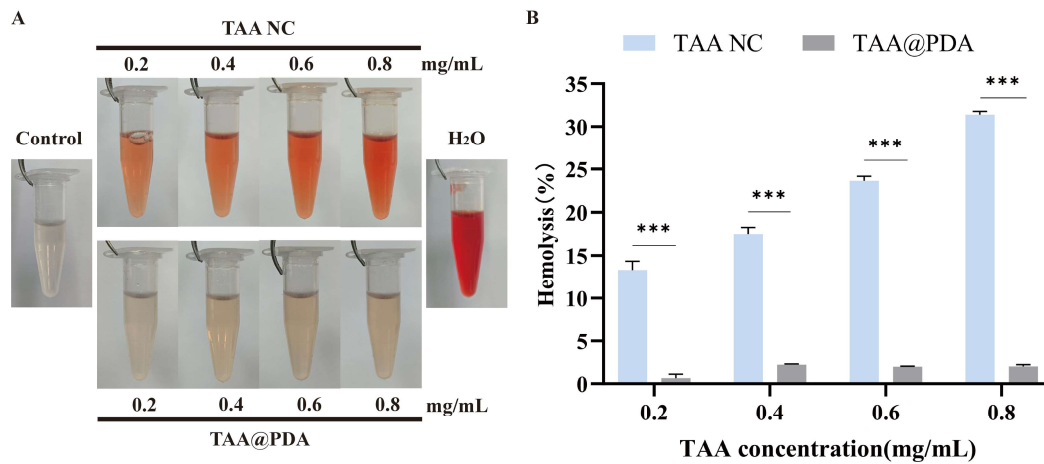


Fig S11. Hemolytic activity of TAA@PDA: (A) hemolysis images; (B) hemolysis rate (n=3, mean±SD). Statistical significance: \*p<0.05, \*\*p<0.01, \*\*\*p<0.001.