

Supporting Information

A novel root canal irrigant enabling rapid formation of a tannic acid–silver nanocoating for sustained antibacterial therapy in root canal infections

Xinzhi Tan^a, Chan He^{a,b}, Xingyu Hu^a, Fangjun Huo^a, Peini Lin^a, Pu Li^a, Weidong

Tian^{a*}, Li Xie^{a*}

^a State Key Laboratory of Oral Diseases & National Center for Stomatology & National Clinical Research Center for Oral Diseases & Engineering Research Center of Oral Translational Medicine, Ministry of Education & National Engineering Laboratory for Oral Regenerative Medicine, West China Hospital of Stomatology, Sichuan University, Chengdu, Sichuan 610041, China.

^b Clinical Research Center for Oral Tissue Deficiency Diseases of Fujian Province & Fujian Key Laboratory of Oral Diseases & Fujian Provincial Engineering Research Center of Oral Biomaterial, School and Hospital of Stomatology, Fujian Medical University, China

* E-mail: drtwd@sina.com

* E-mail: samuelxie2023@gmail.com




Fig. S1 EDX elemental mapping of TA-Ag 0.6. It is derived from the same EDX mapping data as Fig. 2b.




Fig. S2 SEM images and corresponding EDX elemental mapping of root canal walls. (a) Untreated. (b) After irrigation with TA-Ag 1.0.

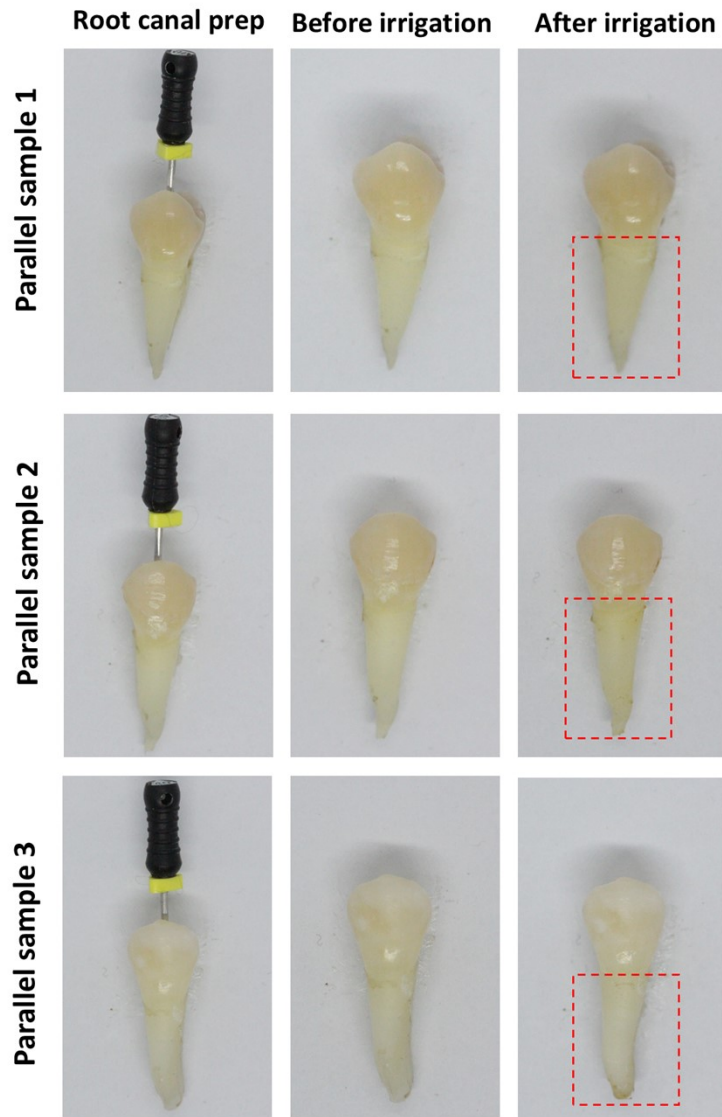


Fig. S3 Visual assessment of tooth discoloration after root canal irrigation with TA-Ag 1.0. The red box encloses the tooth root portion.

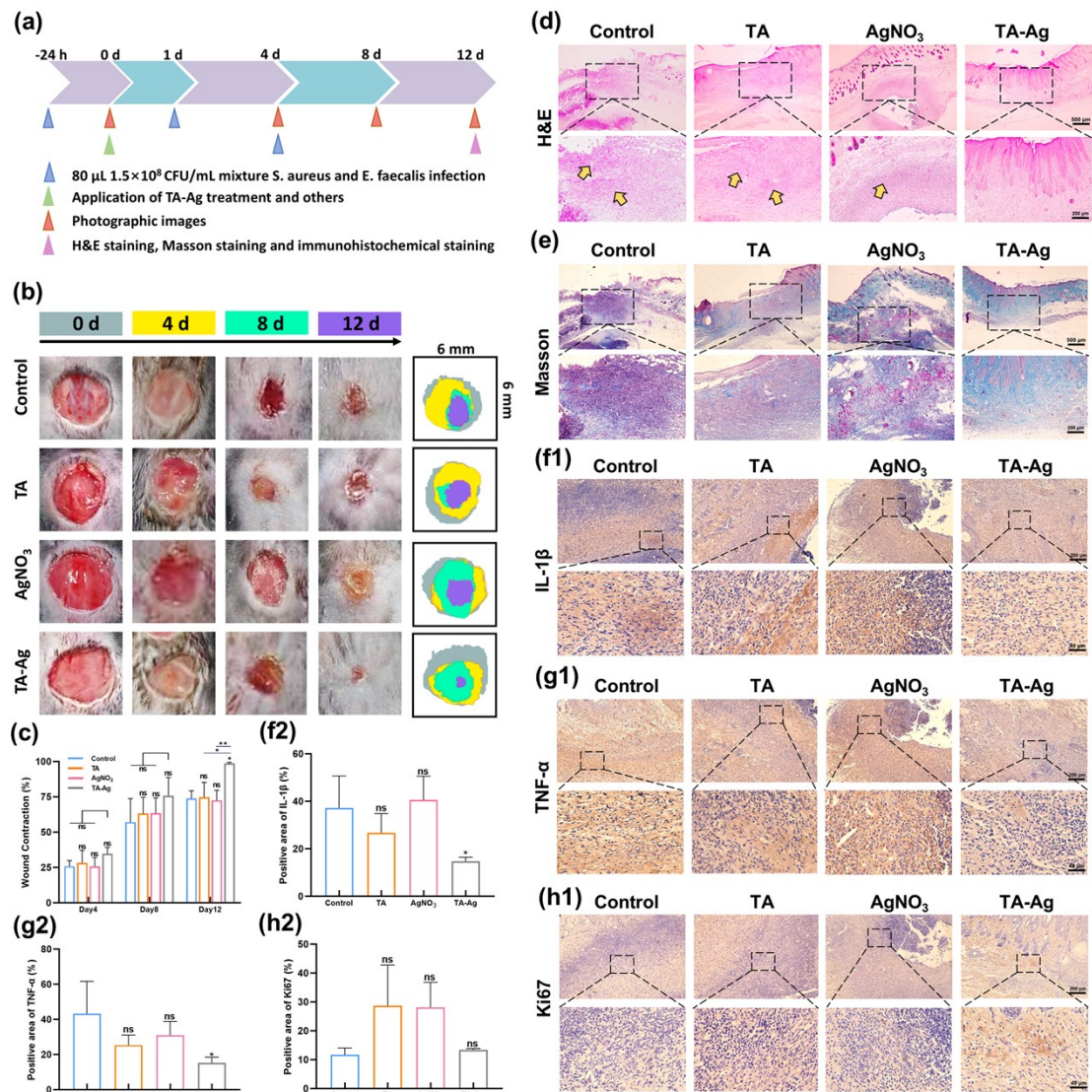


Fig. S4 In vivo therapeutic efficacy of the TA-Ag irrigation system in infectious wound. (a) Schematic illustration of animal model establishment and experimental workflow. (b) Representative photographs of infectious wounds in mice from each group at different time points (scale bar = 6 mm). (c) Corresponding quantitative analysis of wound area for each group at different time points. (d) Representative H&E staining images of infectious skin wound specimens from each group on Day 12 (yellow arrows indicate inflammatory cell infiltration areas). (e) Representative Masson trichrome staining images of infectious skin wound specimens from each group on Day 12. Representative immunohistochemical staining images of wound specimens from each group: (f1) IL-1 β , (g1) TNF- α , and (h1) Ki67. Quantitative analysis of the positive staining areas for (f2) IL-1 β , (g2) TNF- α , and (h2) Ki67 in each group. $n=3$ in all groups. (ns indicates no significance, $*p < 0.05$, $**p < 0.01$).