

Supplementary material_Figure

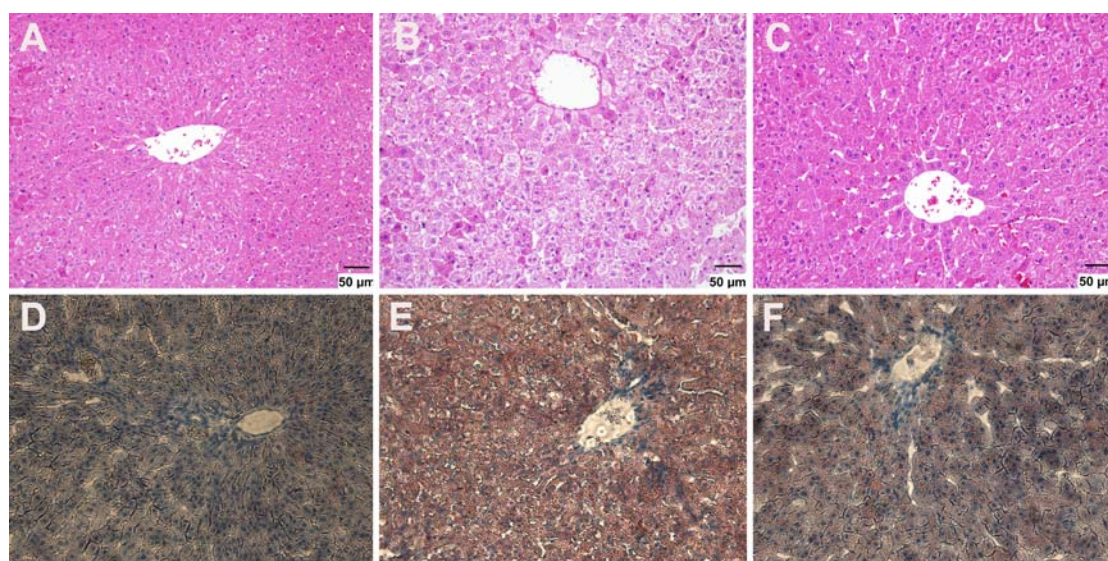


Figure S1 Histopathologic inspection of liver slices from the diet-induced hyperlipidemic hamster and that treated with BBR. HFD induced obviously histopathologic changes in livers(B, E), which could be effectively reversed by BBR(C, F).

A, B, C: hematoxylin-eosin staining

D, E, F: oil red o staining

A, D, Hamsters control; B, E, Hamsters with high fatty diet; C, F, Hamsters with high-fatdiet+BBR (100mg/kg, i.g.).